

CASE REPORT

Open Access



# Pediatric suppurative parotitis caused by *Burkholderia pseudomallei*

Zengzhen Fu<sup>1,2†</sup>, Yingzi Lin<sup>1†</sup>, Qiang Wu<sup>1†</sup> and Qianfeng Xia<sup>1,3\*</sup> 

## Abstract

**Background:** Suppurative parotitis caused by *Burkholderia pseudomallei* has been rarely found outside endemic areas.

**Case presentation:** Herein, we report the recovery of *Burkholderia pseudomallei* from the pus of a suppurative parotitis observed in a 12-year-old boy who lived in Hainan province, China. Specimens of necrotic tissue were collected and sections were stained with hematoxylin and eosin. Pus sample was also collected for bacteriological examination. The suppurative inflammation was observed in the necrotic tissue section and *Burkholderia pseudomallei* were detected in the sample.

**Conclusion:** In this adolescent, *Burkholderia pseudomallei* infection was present in the parotid, which consists of the first report of this bacterium in a parotitis case acquired in China.

**Keywords:** Melioidosis, Parotitis, *Burkholderia pseudomallei*, Pediatrics

## Background

Melioidosis, the disease caused by the bacterium *Burkholderia pseudomallei*, is endemic to Southeast Asia and northern Australia, and parts of South and Central America. Infection with *B. pseudomallei* can be contracted via several routes, including subcutaneous inoculation, ingestion, and likely inhalation [1]. Melioidosis is known as a 'great mimicker' since it may mimic several diseases from pyogenic bacterial infection to tuberculosis, and there is no pathognomonic sign of melioidosis [2–4]. The disease has an acute and a subacute forms and also a chronic relapsing state with associated high mortality. Risk factors for infection include diabetes, alcoholism, renal insufficiency and chronic steroid use [5]. Although melioidosis involves most organs, parotid involvement is rare. To the best of our knowledge, confirmed melioidosis parotitis was not previously reported except for a case that occurred after systemic melioidosis [6]. Therefore, we describe in this report the clinical presentation, management, and outcome of a child with primary melioidosis parotitis.

## Case presentation

The patient was a 12-year-old boy who lived in Dongfang county, Hainan province, a region located in the tropical area of China, who had never traveled abroad. He reported occasionally swimming in the lake of his hometown and had last did it roughly 1 month before the illness onset. This patient presented to the medical department with severe left parotid pain and a 4.0 × 3.5 cm swelling on the left face suggestive of parotitis. The swelling was soft and fluctuant and it was associated with tenderness, warmth and redness. There was no primary focus of infection found in the adjacent draining area. He had no related symptoms of fever, cough, expectoration or weight loss. The patient had no history of diabetes, renal disease, chronic lung disease or excessive alcohol consumption. He had normal vital signs. After parotid aspiration, he immediately received 2 g of ceftazidime intravenously twice a day together with 80 mg of gentamicin three times a day.

The investigation performed at our hospital revealed white blood cell count of  $8.1 \times 10^9/L$  (69 % neutrophils), red blood cell count of  $3.94 \times 10^{12}/L$ , platelet count of  $231 \times 10^9/L$ , hematocrit of 34 %, hemoglobin concentration of 106 g/L, glucose concentration of 6.01 mmol/L, C-reactive protein concentration of 6.3 mg/L, and erythrocyte sedimentation rate was elevated (92 mmHg/1st hour).

\* Correspondence: xiaqianfeng@sina.com

†Equal contributors

<sup>1</sup>Key Laboratory of Translational Medicine for Tropical Diseases (Hainan Medical University), Ministry of Education, Hainan Medical University, Haikou 571199, China

<sup>3</sup>Faculty of Tropical Medicine and Laboratory Medicine, Hainan Medical University, 3 Xue Yuan Road, Haikou, Hainan 570102, China

Full list of author information is available at the end of the article



For histologic analysis, specimens of necrotic tissue taken during the drainage operation were fixed in 4 % paraformaldehyde, sections were stained with hematoxylin and eosin, and suppurative inflammation was observed (Fig. 1). Pus was aspirated from the abscess for bacteriological examination. Subsequently, samples were inoculated on 5 % sheep blood agar and incubated at 37 °C in air. After 48 h, concentric rounded shaped and creamy white colonies were observed on the blood agar (Fig. 2). The isolate proved to be a non-fermenting gram-negative bacillus that was submitted to further identification using the VITEK-2 identification system (BioMérieux, France). VITEK-2 suggested that the isolate was *Burkholderia pseudomallei*, with an excellent level of identification (>99 %), which was confirmed by 16S rRNA gene sequencing. The 16S rRNA gene was amplified by PCR using the primers 27F (5-AGAGTTTGATCCTGGCTCAG-3) and 1525R (5-AAGGAGGTGATCCAGCC-3) [7]. Sequence similarity searches were performed using the BLAST algorithm implemented in the NCBI database.

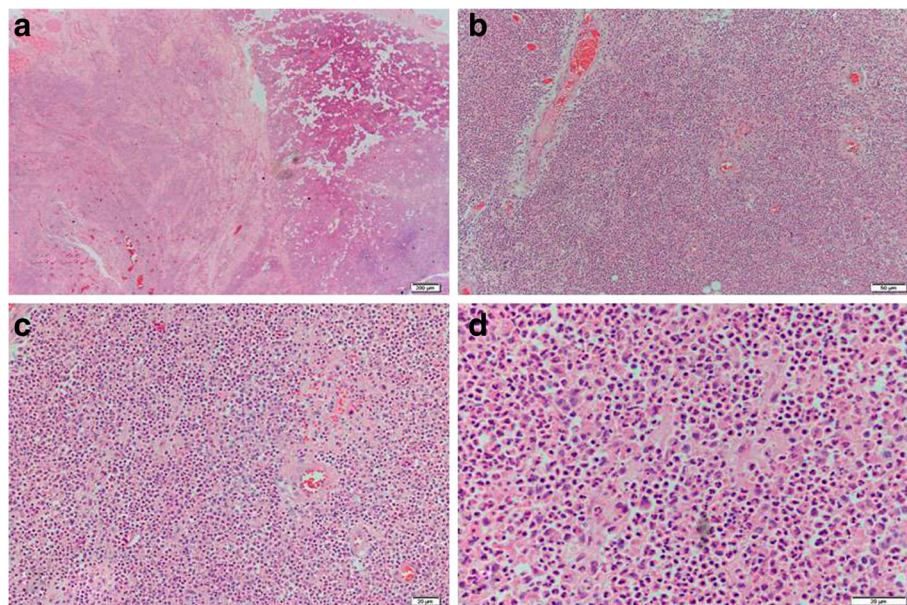
Antibiotic susceptibility testing was performed by broth macrodilution methods. The isolate was susceptible to imipenem (MIC 2 µg/mL) and trimethoprim-sulfamethoxazole (TMP-SMZ) (MIC 2 µg/mL). It was resistant to the following antibiotics: ampicillin (MIC ≥ 32 µg/mL), amikacin (MIC ≥ 32 µg/mL), ceftriaxone (MIC ≥ 32 µg/mL), cefazolin (MIC ≥ 32 µg/mL), nitrofurantoin (MIC ≥ 32 µg/mL), gentamicin (MIC ≥ 32 µg/mL), cefepime (MIC ≥ 32 µg/mL), levofloxacin (MIC ≥ 32 µg/mL), ceftazidime (MIC ≥ 32 µg/mL), ciprofloxacin (MIC ≥ 32 µg/mL) and piperacillin/tazobactam (MIC ≥

32 µg/mL). According to the laboratory data, the therapy was therefore changed to intravenous imipenem and oral TMP-SMZ for 4 weeks. The patient was discharged with an additional treatment of 12 weeks of oral TMP-SMZ.

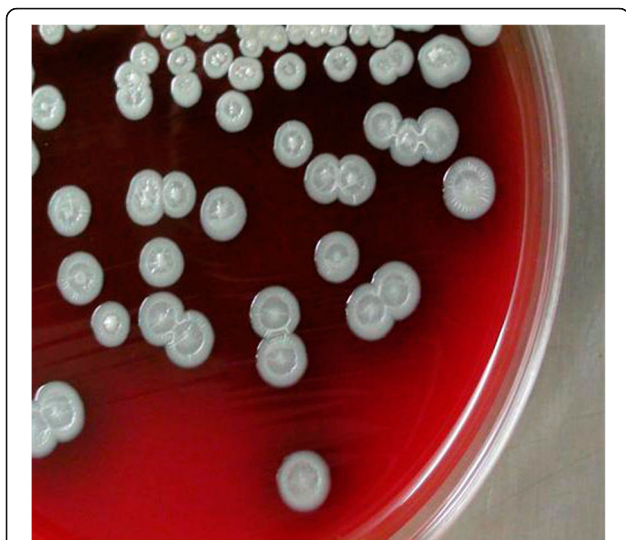### Conclusions

Although data are lacking with regard to the exact locations, eight human cases of melioidosis were registered around Hainan province [8]. In this study, we have described a case of *B. pseudomallei* suppurative parotitis in China. Our patient was from Dongfang district, which is situated in the tropical zone of China. This was essentially a locally acquired case, as this patient had never travelled to any other country. To our knowledge, this is the first description of *B. pseudomallei* in a parotitis patient acquired in China.

Best clinical judgment and focused microbiological investigations are very important for early diagnosis [9, 10]. In this case, cultures from pus grew *B. pseudomallei* and the blood cultures were negative. The clinicians should provide an early appropriate antibiotic treatment to reduce the risk of death caused by melioidosis. However, therapeutic options for the treatment of melioidosis are limited as *B. pseudomallei* is resistant to numerous antibiotics, including aminoglycoside, penicillin, narrow- and expanded-spectrum cephalosporin and macrolide. *B. pseudomallei* is generally susceptible to TMP-SMZ, broad-spectrum cephalosporin and carbapenem [11]. High-dose intravenous ceftazidime is currently the first antibiotic of choice for the recommended treatment of acute melioidosis [12]. In this case, the isolate was



**Fig. 1** Histopathologic evaluation of parotid tissue specimens from the patient. Suppurative inflammation is observed in the parotid (a, b, c and d). Hematoxylin and eosin stain, original magnification: (a) 20×, (b) 100×, (c) 200× and (d) 400×. Scale bars indicate (a) 200 µm, (b) 50 µm, or (c and d) 20 µm



**Fig. 2** *Burkholderia pseudomallei* colonies on blood agar: they are creamy white with concentric ring-like pattern

resistant to ceftazidime and most other antibiotics. It was only susceptible to imipenem and TMP-SMZ. Our patient recovered following treatment with intravenous imipenem and oral TMP-SMZ for 4 weeks, and 3 months of oral TMP-SMZ, as per the recommendations. He was doing well on follow-up. Intravenous imipenem and oral TMP-SMZ may prove efficacious for the treatment of suppurative parotitis caused by *B. pseudomallei*.

The presence of melioidosis may lead to several of deaths since most laboratories of Hainan have no experience in recognizing this organism. The cases are common enough that China is listed as one of the endemic countries for melioidosis. A high index of suspicion is needed to diagnose these complications, even in endemic regions like ours, as these complications can be life threatening, and melioidosis is not commonly identified as the source of severe presentations. Based on the present report, we believe that infections caused by *B. pseudomallei* should be included in the differential diagnosis of suppurative parotitis in Hainan, China.

#### Acknowledgements

We thank Dr. Xian W of Hainan Maternity and Child Healthcare Hospital, Haikou, China, for his assistance in epidemiological investigation.

#### Funding

This work was financially supported by National Natural Science Foundation of China (81360240 and 81560002), Social Development and Scientific and Technological Projects of Hainan Province (SF201415).

#### Authors' contributions

ZF designed the study and revised the data. YZL was involved in the epidemiological investigation. QW was responsible for follow-up. QFX was responsible for professional guidance. All authors read and approved the final version of the manuscript.

#### Competing interests

The authors declare that they have no competing interests.

#### Consent for publication

Written informed consent was obtained from the patient's father for publication of this article.

#### Ethics approval and consent to participate

The present study was approved by the Ethics Committee of Hainan Medical University (Haikou, China; CEEA2015-213) and the patient's father provided written informed consent.

#### Author details

<sup>1</sup>Key Laboratory of Translational Medicine for Tropical Diseases (Hainan Medical University), Ministry of Education, Hainan Medical University, Haikou 571199, China. <sup>2</sup>Department of Pediatrics, Hainan Maternity and Child Healthcare Hospital, Haikou 571168, China. <sup>3</sup>Faculty of Tropical Medicine and Laboratory Medicine, Hainan Medical University, 3 Xue Yuan Road, Haikou, Hainan 570102, China.

Received: 5 July 2016 Accepted: 5 November 2016

Published online: 09 November 2016

#### References

- Wiersinga WJ, Currie BJ, Peacock SJ. Melioidosis. *N Engl J Med*. 2012; 367(11):1035–44.
- Loveleena, Chaudhry R, Dhawan B. Melioidosis; the remarkable imitator: recent perspectives. *J Assoc Physicians India*. 2004;52:417–20.
- Dias-Baptista IMF, Usó SMRS, Marcondes-Machado J. Trends in multidrug-resistant tuberculosis. *J Venom Anim Toxins incl Trop Dis*. 2008;14(2):203–23.
- Tyagi P, Shah V, Sharma P, Bansal N, Singla V, Kumar A, et al. Melioidosis presenting as fever and jaundice: a rare presentation. *J Clin Exp Hepatol*. 2014;4(2):172–4.
- Limmathurotsakul D, Chaowagul W, Chierakul W, Stepniewska K, Maharjan B, Wuthiekanun V, et al. Risk factors for recurrent melioidosis in northeast Thailand. *Clin Infect Dis*. 2006;43(8):979–86.
- Shivbalan S, Reddy N, Tiru V, Thomas K. Systemic melioidosis presenting as suppurative parotitis. *Indian Pediatr*. 2010;47:799–801.
- Weisburg WG, Barns SM, Pelletier DA, Lane DJ. 16S ribosomal DNA amplification for phylogenetic study. *J Bacteriol*. 1991;173(2):697–703.
- Yang S, Tong S, Mo C, Jiang Z, Yang S, Ma Y, et al. Prevalence of human melioidosis on Hainan Island in China. *Microbiol Immunol*. 1998;42(9):651–65.
- Currie BJ, Ward L, Cheng AC. The epidemiology and clinical spectrum of melioidosis: 540 cases from the 20 year Darwin prospective study. *PLoS Negl Trop Dis*. 2010;4(11):e900.
- Meumann EM, Cheng AC, Ward L, Currie BJ. Clinical features and epidemiology of melioidosis pneumonia: results from a 21-year study and review of the literature. *Clin Infect Dis*. 2012;54(3):362–9.
- Chaowagul W, Chierakul W, Simpsom AJ, Short JM, Stepniewska K, Maharjan B, et al. Open-label randomized trial of oral trimethoprim-sulfamethoxazole, doxycycline, and chloramphenicol compared with trimethoprim-sulfamethoxazole and doxycycline for maintenance therapy of melioidosis. *Antimicrob Agents Chemother*. 2005;49(10):4020–5.
- Steward J, Piercy T, Lever MS, Nelson M, Simpson AJ, Brooks TJ. Comparison of gatifloxacin, moxifloxacin and ciprofloxacin for treatment of experimental *Burkholderia pseudomallei* infection. *J Antimicrob Chemother*. 2005;55(4):523–7.

Submit your next manuscript to BioMed Central and we will help you at every step:

- We accept pre-submission inquiries
- Our selector tool helps you to find the most relevant journal
- We provide round the clock customer support
- Convenient online submission
- Thorough peer review
- Inclusion in PubMed and all major indexing services
- Maximum visibility for your research

Submit your manuscript at  
www.biomedcentral.com/submit

